



## Abnormal cortical thickness in heroin-dependent individuals

Meng Li<sup>a,1</sup>, Junzhang Tian<sup>b,1</sup>, Ruibin Zhang<sup>a</sup>, Yingwei Qiu<sup>b</sup>, Xue Wen<sup>a</sup>, Xiaofen Ma<sup>b</sup>,  
Junjing Wang<sup>a</sup>, Yong Xu<sup>a</sup>, Guihua Jiang<sup>b,\*</sup>, Ruiwang Huang<sup>a,\*\*</sup>

<sup>a</sup> Center for the Study of Applied Psychology, Key Laboratory of Mental Health and Cognitive Science of Guangdong Province, School of Psychology, South China Normal University, Guangzhou 510631, PR China

<sup>b</sup> Department of Medical Imaging, Guangdong No. 2 Provincial People's Hospital, Guangzhou 510317, PR China

### ARTICLE INFO

#### Article history:

Accepted 9 October 2013

Available online 17 October 2013

#### Keywords:

Addiction  
Cortical thickness  
Duration of heroin use  
Vertex-wise  
ROI-wise

### ABSTRACT

Accumulating evidence from brain structural imaging studies on heroin dependence has supported links between brain morphological alterations and heroin exposure, particularly in gray matter volume or gray matter density. However, the effects of heroin exposure on cortical thickness and the relationship between cortical thickness and heroin addiction are not yet known. In this study, we acquired 3D high-resolution brain structural magnetic resonance imaging (MRI) data from 18 heroin-dependent individuals (HDIs) and 15 healthy controls (HCs). Using FreeSurfer, we detected abnormalities in cortical thickness in the HDIs. Based on a vertex-wise analysis, the HDIs showed significantly decreased cortical thickness in the bilateral superior frontal, left caudal middle frontal, right superior temporal, and right insular regions compared to the HCs but significantly increased cortical thickness in the left superior parietal, bilateral lingual, left temporal pole, right inferior parietal, right lateral occipital, and right cuneus regions. To supplement these results, a subsequent ROI-wise analysis was performed and showed decreased cortical thickness in the left superior frontal sulcus, left precuneus gyrus, left calcarine sulcus, left anterior transverse collateral sulcus, and the right medial occipital–temporal and lingual sulcus. These regions partially overlapped with the areas identified using the vertex-wise analysis. In addition, we found that the thickness in the right superior frontal and right insular regions was negatively correlated with the duration of heroin use. These results provide compelling evidence for cortical abnormality in HDIs and also suggest that the duration of heroin use may be a critical factor associated with the brain alteration.

© 2013 Elsevier Inc. All rights reserved.

### Introduction

Drug addiction is characterized by a compulsion to seek and take the drug, a loss of control in limiting its intake, and the emergence of a negative emotional state (e.g., dysphoria, anxiety, and irritability) when access to the drug is prevented (Goldstein and Volkow, 2002). Previous studies showed that drug addiction can lead to changes in brain structure (Daumann et al., 2011; Ersche et al., 2012; Liu et al., 2009a; Lyoo et al., 2006) and function (Daglish et al., 2003; Hester et al., 2009; Ma et al., 2010). Out of all the addicting drugs, heroin addiction poses one of the most major threats to the public health and social security of China (Tang et al., 2006). Therefore, the relationship

between heroin abuse and brain structure needs to be thoroughly studied.

The morphology of cortical gray matter is commonly assessed using T1-weighted MRI with automated computerized methods such as voxel-based morphometry (VBM) and surface-based morphometry (SBM). Most previous studies in this field have analyzed regional alterations in the brain gray matter volume or density in heroin users in an apparent response to heroin use (Liu et al., 2009a; Lyoo et al., 2006; Wang et al., 2012; Yuan et al., 2009, 2010b). For example, Liu et al. (2009a) found reductions in brain gray matter volume in the prefrontal cortex (PFC), supplementary motor cortex (SMC), and cingulate cortices in heroin-dependent individuals (HDIs) compared to controls. Yuan et al. (2009, 2010b) showed heroin-related decreased gray matter volume in the PFC, insular (INS), anterior cingulate (ACC) and temporal regions and also found that the gray matter volume in these areas was negatively correlated with the duration of heroin use in HDIs. Wang et al. (2012) studied abstinent heroin users and reported decreased gray matter volume in the frontal, cingulate, and occipital regions.

However, VBM is especially susceptible to the degree of smoothing, the strategies used in registration, and the choice of a normalization template (Bookstein, 2001; Jones et al., 2005). In addition, VBM analysis may provide a mixed measure of gray matter alteration combined with abnormalities in cortical thickness, cortical surface area, and cortical

\* Corresponding author. Fax: +86 20 8417 8990.

\*\* Correspondence to: R. Huang, Centre for the Study of Applied Psychology, Key Laboratory of Mental Health and Cognitive Science of Guangdong Province, School of Psychology, South China Normal University, Guangzhou 510631, PR China. Fax: +86 20 8521 6033.

E-mail addresses: [GH.jiang2002@163.com](mailto:GH.jiang2002@163.com) (G. Jiang), [ruiwang.huang@gmail.com](mailto:ruiwang.huang@gmail.com) (R. Huang).

<sup>1</sup> These authors contributed equally to this work.

folding (Hester et al., 2009; Voets et al., 2008). These factors have the potential to reduce the sensitivity of this method for detecting significant effects of brain structural abnormalities in diseased brains. Thus, SBM was proposed to assess brain structural changes, especially cortical thickness (Voets et al., 2008). SBM, which unlike VBM considers the whole brain gray matter, derives morphometric measures from geometric models of the cortical surface. Cortical thickness has been shown to be sensitive to normal aging (Hutton et al., 2009; Tamnes et al., 2010), intelligence (Choi et al., 2008; Shaw et al., 2006), cognitive performance (Dickerson et al., 2008), mental disorders, and pathological changes (Almeida et al., 2010; Habets et al., 2011), and seems to be capable of reflecting the architecture of the cerebral column (Pontou et al., 2008). Hutton et al. (2009) has shown that cortical thickness could provide a more sensitive measure of age-associated decline compared to the gray matter volume measure typically used in VBM studies. The Human Connectome Project (HCP) (Glasser et al., 2013; Van Essen et al., 2013) also introduced the term 'grayordinate' that represents gray matter in a way that respects its natural geometry by defining surface vertices for the cerebral cortex and voxels for the subcortical gray matter. SBM makes it possible to subdivide the gray matter volume into cortical thickness and cortical area. These two factors are likely to yield more precise information about underlying disease mechanisms (Hutton et al., 2009; Sowell et al., 2004) and may aid in understanding the neuropathophysiology of drug-related brains.

Cortical thickness might be a more appropriate measure than gray matter volume when trying to assess morphologic abnormalities in brain structure (Clarkson et al., 2011; Hutton et al., 2009; Klein et al., 2010; Lusebrink et al., 2013). Several previous studies used vertex-wise SBM to analyze cortical thickness and found abnormalities in the brain structures of a variety of substance users, such as smokers (Kuhn et al., 2010; Makris et al., 2008), alcohol users (Yang et al., 2012), marijuana users (Lopez-Larson et al., 2011), and amphetamine-type stimulant users (Koester et al., 2012; Lawyer et al., 2010). In addition, based on the Destrieux cortical atlas (Destrieux et al., 2010; Fischl et al., 2004), which uses gyral and sulcal structures to parcellate each cortical hemisphere into 74 regions of interest (ROI), several studies have used ROI-wise SBM analysis to detect abnormalities in regional brain morphology related to long term motor training in healthy subjects (Palaniyappan and Liddle, 2012), memory rehabilitation after traumatic brain injury (Strangman et al., 2010), socioeconomic status on children's brain structure (Jednorog et al., 2012), patients with migraine (Messina et al., 2013), and human immunodeficiency virus (HIV) patients (Kallianpur et al., 2012). However, to the best of our knowledge, very few studies have explored cortical thickness abnormalities in HDIs, except that Walhovd et al. (2007) reported cortical thickness alterations in the children who were exposed to opiates and other substances in utero.

In order to understand the neurobiological basis of drug addiction, researchers have begun to explore the effects of drug use on brain structure and function (Goldstein and Volkow, 2011; Goldstein et al., 2009; Naqvi and Bechara, 2010; Reid et al., 2008; Schwartz et al., 2010; Tanabe et al., 2009; Volkow et al., 2013). Neuroimaging studies have indicated a key involvement of the PFC and INS in cognitive impairments, such as impulsiveness (Lee and Pau, 2002; Lee et al., 2001; Moreno-Lopez et al., 2012) and difficulties in executing response suppression tasks (Jan et al., 2012; Swann et al., 2002) and performing decision-making tasks (Fu et al., 2008; Lee et al., 2005; Yang et al., 2009), in drug addiction. For example, Lee et al. (2005) found that HDIs took a much shorter time to complete the more demanding part of a task but committed more errors than normal controls. Fu et al. (2008) reported heroin had a negative impact on the function of PFC, ACC, INS, and limbic system and induced an impaired response inhibition function even months into abstinence. Yang et al. (2009) found that heroin users showed a decreased response to neutral cues and an increased response to heroin cues in the prefrontal systems. These findings indicated that dynamic response patterns in the PFC system characterize the impaired brain control functions in heroin users. Using graph theoretical analysis,

Liu et al. (2009b) found dysfunctional connectivity, which may contribute to decreased self-control and impaired inhibition, in the PFC, ACC, and INS in chronic heroin users. Moreover, numerous functional imaging studies have found both PFC and INS activation in other types of substance dependence (Brody et al., 2002; Filbey et al., 2009; Kilts et al., 2001; Naqvi and Bechara, 2009). In a study of heavy cigarette smokers, Brody et al. (2002) reported that the intensity of craving was positive correlated with glucose metabolism in the bilateral INS, DLPFC, and OFC. Kilts et al. (2001) detected increased activation in the left INS and ACC when comparing drug use imagery to neutral imagery in cocaine users. Filbey et al. (2009) demonstrated greater activation in the reward pathway (INS and ACC) in response to a marijuana cue compared to a neutral cue in abstinent marijuana users.

Previous studies also suggested that the duration of heroin use is a critical variable for understanding the effects of heroin on structural and functional abnormalities (Ersche et al., 2006; Qiu et al., 2013; Yuan et al., 2009, 2010a). For example, Ersche et al. (2006) reported that task-related activation of the left orbital frontal cortex (OFC) was associated with the duration of intravenous heroin use. Yuan et al. (2010a) performed a resting state fMRI study in HDIs and found that the functional connectivity between the posterior cingulate/precuneus and the right cerebellum was negative correlated with the duration of heroin addiction. And a recent study by Qiu et al. (2013) showed that the ratio of gray matter volume in the PFC to the total brain gray matter volume was negative correlated with the duration of heroin use. As to other substance dependence, for example, in the cocaine users, the years of cocaine use was negative correlated with local gray matter volumes in the bilateral middle frontal gyrus (MFG), left superior frontal gyrus (SFG), INS, amygdala (AMYG), uncus (UNC), and middle temporal gyrus (MTG) (Barros-Loscertales et al., 2011).

Based on these previous structural and functional studies of addiction, we hypothesized that cortical thickness would be altered in some areas of the brain, especially in the frontal and insular regions (Goldstein and Volkow, 2011; Goldstein et al., 2009; Naqvi and Bechara, 2010), in the heroin users and that the duration of heroin use would be associated with altered cortical thickness. In order to test this hypothesis, we calculated the cortical thickness for the HDI and control groups using vertex-wise and ROI-wise SBM approaches.

## Methods

### Subjects and data acquisition

Eighteen heroin-dependent individuals (HDIs: aged 27–47 years, mean = 36.11 ± 5.72 years, 1 female, Han Chinese population) were recruited from the Addiction Medicine Division of the Guangdong No. 2 Provincial People's Hospital. Each of the HDIs was screened using the Structured Clinical Interview (SCID-IV) for the Statistical Manual of Mental Disorders, Fourth Edition (DSM-IV), to confirm the diagnosis of opiate dependence (Spitzer et al., 1992). Urine tests with a positive finding for heroin use were acquired before enrolling in the treatment program. The HDIs were abstinent for six or seven days at the time of the scan and showed some withdrawal symptoms, such as anxiety, angry, sleeplessness and constipation, as described by their medical carers. For each of the HDIs, heroin dosage, methadone dosage, nicotine use, and education are shown in Inline Supplementary Table S1 in the Supplemental material. Furthermore, none of the HDIs had any known use of any other types of illicit drugs based on a laboratory report and an interview conducted by a clinical psychologist. In order to avoid confounding factors from comorbidities with heroin use, we set the following exclusion criteria for the HDIs: no dependence on other psychoactive drugs and no history of drug use other than heroin and nicotine (smoking). We also recruited fifteen healthy volunteers as the controls (HCs: aged 28–48 years, mean = 36.80 ± 8.53 years, 3 females). All subjects were right-handed according to their self-report. Table 1 lists the demographic details for all subjects.

Inline Supplementary Table S1 can be found online at <http://dx.doi.org/10.1016/j.neuroimage.2013.10.021>.

For each subject in the current study, the other exclusion criteria were as follows: no history of neurological illness, no head injury, no diagnosis of either schizophrenia or affective disorder, no abnormality on the MRI scan, no additional substance abuse/dependence diagnosis, and no contraindications for MRI scanning. This study was approved by the Research Ethics Review Board of Institute of Mental Health, the Southern Medical University in Guangzhou, China. Written informed consent was obtained from each subject.

MRI data were acquired on a 1.5 T Philips Achieva Nova Dual MR scanner in the Department of Medical Imaging, Guangdong No. 2 Provincial People's Hospital. Each subject lay supine with their head snugly fixed by a belt and foam pads. T1-weighted 3D high resolution brain structural images were acquired using a fast field echo (FFE) pulse sequence with repetition time (TR) = 25 ms, echo time (TE) = 4.1 ms, flip angle (FA) = 30°, acquisition matrix = 256 × 256, field of view (FOV) = 230 mm<sup>2</sup>, slice thickness = 1.0 mm, and 160 sagittal slices.

#### Data processing

Cortical thickness was estimated using 3D brain structural images with the FreeSurfer software package (Version 5.0.0, <http://surfer.nmr.mgh.harvard.edu>), a widely documented and automated program for reconstructing brain cortical surfaces (Dale et al., 1999; Fischl et al., 1999a, 1999b). In short, we processed the T1-weighted 3D brain structural images by removing the non-brain tissue, transforming the brain into a Talairach-like space, and performing a segmentation to obtain the brain gray and white matters. The boundary or interface between the brain white and gray matters was tessellated and the topological defects in the gray-white estimate were fixed automatically. After we performed intensity normalization and determined the transitions between the brain gray matter and white matter, we identified the boundary between the pial and gray matter by detecting the greatest shift in intensity through cortical surface deformation. Thus, we produced a linked mesh surface which was covered by the triangles. We took each point shared by adjacent triangles on the cortical surface as a vertex. For each subject, the entire cortex was then visually inspected for any inaccuracies in segmentation and manually corrected if necessary. Cortical thickness was measured as follows: we estimated the shortest distance between a given point on the estimated pial surface and the gray-white matter boundary and the shortest distance between a given point on the gray-white matter boundary and the estimated pial surface at each vertex, and then averaged these two values to estimate the cortical thickness. The surface of the gray-white matter boundary was inflated, and between-subject differences in the cortical folding patterns of the gyri and sulci were normalized. The reconstructed brain of each subject was morphed and registered to an average spherical surface using a spherical transformation. A thickness measurement at each vertex on the cortical surface was mapped for each subject on a common spherical coordinate

**Table 1**  
Demographic characteristics of the heroin-dependent individuals (HDIs) and the healthy controls (HCs).

Characteristics	HDIs (n = 18)	HCs (n = 15)	p-value
Age (years)	36.11 ± 5.72	36.80 ± 8.53	0.79
Gender (female/male)	1/17	3/12	0.21
Education (years)	9.61 ± 2.75	9.40 ± 4.69	0.88
Nicotine (# of cigarettes/day)	17.78 ± 13.09	11.67 ± 12.49	0.18
Total intracranial volume (cm <sup>3</sup> )	1538.3 ± 146.9	1458.4 ± 149.1	0.13
Heroin use (years)	12 ± 5.32	N/A	
Range (years)	5–20		
Heroin dosage (g/day)	0.62 ± 0.31	N/A	
Range (g/day)	0.10–1.00		
Methadone dosage (g/day)	36.67 ± 28.65	N/A	
Range (g/day)	0–90		

system using a spherical transformation. The normalized cortical thickness was smoothed using a Gaussian kernel with a full-width-half-maximum (FWHM) of 10 mm.

#### Statistical analyses

Two-sample *t*-tests were performed to assess differences in age, education, and cigarette smoking, and a chi-square test was used to assess the gender composition between the HDI and HC groups using SPSS 17.0.

#### Comparisons of brain morphometry

For each vertex, a general linear model (GLM) was used to detect significant differences in cortical thickness between the HDIs and the HCs. The left and right hemispheres were analyzed separately. We regressed out the effects of age, nicotine usage, education, and total intracranial volume (TIV). A Monte Carlo simulation cluster analysis with 10,000 iterations and a cluster threshold of  $p < 0.05$  was performed to correct for multiple comparisons. Only the surviving cluster is shown in this study.

In order to better understand thickness alterations in the HDIs, we also performed an ROI-wise SBM analysis to supplement the findings obtained by the vertex-wise analysis on the whole cortex. The reason is that the vertex-wise SBM analysis was only performed on the vertex, which does not correspond to specific brain sulco-gyral structures or specific brain functional regions. This may cause difficulties when comparing the results with other similar studies. In the calculation, we adopted the Destrieux atlas, which parcellates the human brain based on the precise localization of 74 gyral or sulcal regions, regions of interest (ROIs), for each of the hemispheres (Destrieux et al., 2010; Fischl et al., 2004), to perform an ROI-wise analysis on the cortical thickness. The details of the alterations in cortical thickness for each ROI in the HDIs are presented in Inline Supplementary Table S2 in the Supplementary material. Each ROI in the Destrieux atlas contains information about either gyral or sulcal structures in the human brain. For the ROI-wise analysis, we utilized a nonparametric permutation test (10,000 times) and took age, nicotine usage, education, and total intracranial volume (TIV) of the subjects as covariates to determine significant between-group differences in the average thickness for each ROI ( $p < 0.05$ , uncorrected).

Inline Supplementary Table S2 can be found online at <http://dx.doi.org/10.1016/j.neuroimage.2013.10.021>.

For the ROI-wise SBM analysis, the choice of atlas may affect the results of between-group comparisons in thickness. To check this assumption, we also performed the ROI-wise SBM analysis based on the Desikan–Killiany cortical atlas (Desikan et al., 2006) which subdivides each hemisphere into 34 regions. For all ROIs in the Desikan–Killiany atlas, the detailed thickness alterations in the HDIs are listed in Inline Supplementary Table S3 (the Supplementary material).

Inline Supplementary Table S3 can be found online at <http://dx.doi.org/10.1016/j.neuroimage.2013.10.021>.

In order to compare the alterations in cortical thickness throughout the whole cortex, we calculated the relative alterations in critical thickness for a given ROI using the following equation

$$RA = (HDIs - HCs) / HCs \quad (1)$$

where HDIs (HCs) represents the group averaged cortical thickness in the HDIs (HCs) group for a given ROI. For each of the 148 ROIs in the Destrieux atlas, we estimated the relative alteration in the cortical thickness in the HDIs compared to the HCs.

#### Correlations

Based on the results of the vertex-wise analysis, we estimated the partial correlations between the cortical thickness of each significant cluster and the duration of heroin use for the HDI participants. The aim was to determine whether structural deficits were related to the



duration of heroin use. We first determined significant clusters on a statistical parametric map of the between-group differences in cortical thickness, mapped each of these clusters onto each individual cortical surface and extracted the mean cortical thickness. Then we calculated the partial correlation between the mean cortical thickness of each significant cluster and the duration of heroin use, the heroin dosage, the methadone dosage while taking age, nicotine usage, education, and total intracranial volume (TIV) as covariates.

## Results

### Participant characterization

We found no significant differences in age, gender, education, total intracranial volume (TIV), and cigarette smoking between the HDIs and the HCs (Table 1).

### Alterations of brain morphometry

#### Vertex-wise analysis

For the vertex-wise SBM analysis across the whole brain, we found significant alterations in cortical thickness in twelve clusters, 5 increases and 7 decreases, in the HDIs compared to the HCs ( $p < 0.05$ , corrected, Table 2). Fig. 1a shows the location of these clusters on the cortical surface and Table 2 lists detailed information of these clusters. The clusters with decreased thickness were primarily located in the bilateral superior frontal (SFC.L and SFC.R), left caudal middle frontal (cMFC.L), right insular (INS.R), and right superior temporal (STC.R) regions. The clusters with increased thickness were primarily located in the bilateral lingual gyrus (LING.L and LING.R), left superior parietal (SPC.L), left temporal pole (TP.L), right lateral occipital (LOC.R), right inferior parietal (IPC.R), and right cuneus (CUN.R) regions.

For each cluster listed in Table 2, we first calculated the mean cortical thickness for each individual, and then estimated the correlations between the mean cortical thickness and the duration of heroin use for the HDIs. The statistical analysis revealed that the mean cortical thickness was significantly negatively correlated with the duration of heroin use in the SFC.R ( $r = -0.56$ ,  $p = 0.032$ ) and marginally significantly in the INS.R ( $r = -0.44$ ,  $p = 0.065$ ) in the HDIs (Fig. 1b). For illustrative purposes, we also plotted the cortical thickness in the SFC.R and in the INS.R for each of the HCs (Fig. 1b). However, we found no significant correlation between the mean cortical thickness and the duration of heroin use in the other clusters listed in Table 2.

Unfortunately, we found no significant correlations between the heroin dosage and thickness as well as between the methadone dosage and thickness at the identified abnormal regions in HDIs.

#### ROI-wise analysis

Fig. 2 shows a plot of the cortical regions that showed significant between-group differences in cortical thickness according to the ROI-wise SBM analysis. In nine of the 148 regions in the Destrieux atlas, we found that the cortical thickness was uniformly significantly decreased in the HDIs compared to the HCs (Table 3). The areas of significantly decreased cortical thickness were found in the left precuneus gyrus, left calcarine sulcus, left inferior circular insular sulcus, left superior frontal sulcus, and the right medial occipital–temporal and lingual sulcus in the HDIs, findings which were consistent with the ones derived from the vertex-wise SBM analysis. In addition, the ROI-wise SBM analyses also revealed significantly decreased cortical thickness in the bilateral anterior transverse collateral sulcus, left inferior temporal sulcus, and right orbital sulci in the HDIs compared to the HCs.

We overlapped the abnormal cortical regions in thickness detected from both the vertex-wise and ROI-wise (Destrieux atlas) analyses and presented the results in Fig. 3. Both of the SBM analyses revealed that, compared to the HCs, the HDIs showed abnormal cortical thickness in the left superior frontal sulcus, left precuneus gyrus, left calcarine sulcus, left anterior transverse collateral sulcus, and the right medial occipital–temporal and lingual sulcus.

For each ROI showing significant between-group differences (Table 3), we also performed a statistical correlation analysis. Unfortunately, we found no significant correlations between the group averaged cortical thickness and the duration of heroin use for any of the regions listed in Table 3.

Fig. 4 shows a plot of the relative differences in cortical thickness in the HDIs compared to the HCs according to Eq. (1), based on the Destrieux cortical atlas. The positive (negative) value of the relative alteration indicates an increase (decrease) in thickness for a given ROI in the HDIs compared to the HCs. For the 148 regions defined in the Destrieux cortical atlas, we found that the greatest differences in cortical thickness in the HDIs were primarily located in the frontal, and in the occipital lobes. Similarly, we performed ROI-wise SBM analysis based on the Desikan–Killiany cortical atlas. The relative alteration in thickness in the HDIs compared to the HCs is presented in Inline Supplementary Figure S1 in the supplemental material. The absolute alterations in thickness in the HDIs are listed in Inline Supplementary Tables S2 and S3 in the supplemental material, respectively, for the Destrieux and Desikan–Killiany cortical atlases.

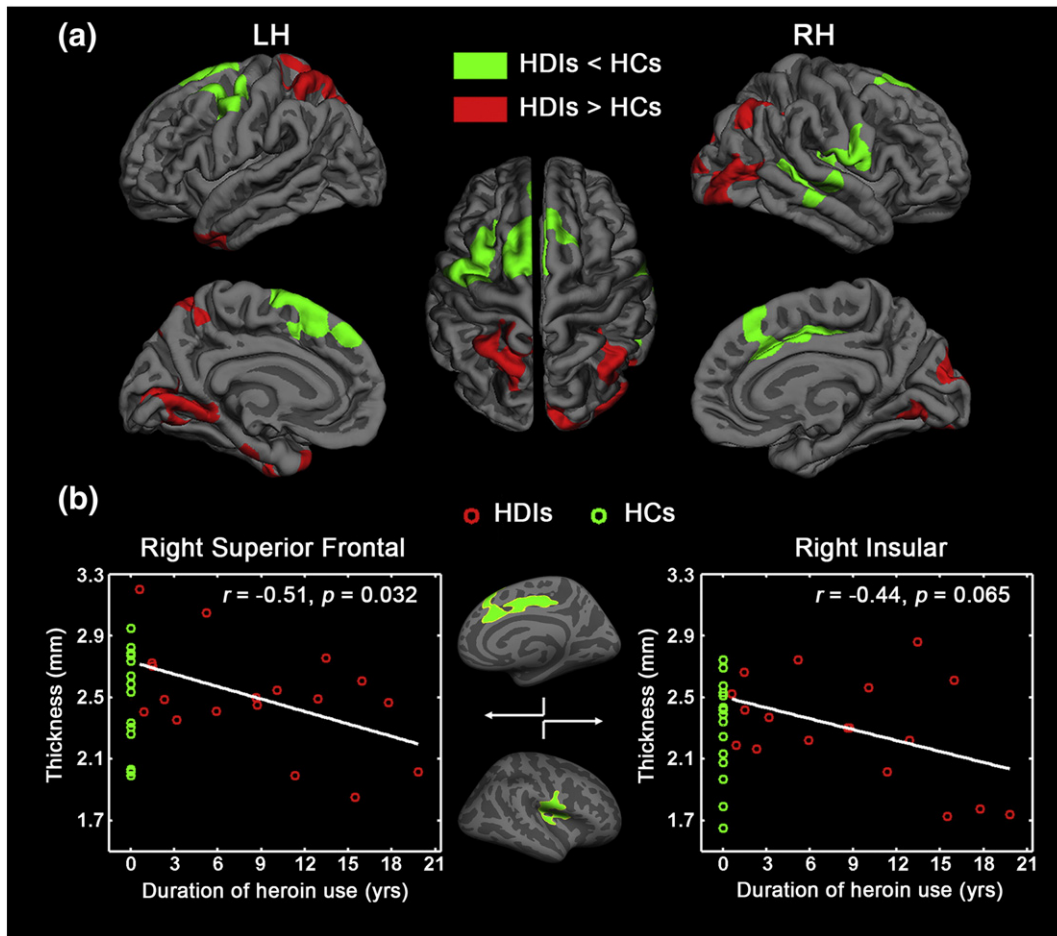
Inline Supplementary Figure S1, Tables S2 and S3 can be found online at <http://dx.doi.org/10.1016/j.neuroimage.2013.10.021>.

## Discussion

Using two surface-based SBM (vertex- and ROI-wise) approaches, we explored differences in cortical thickness between a group of heroin

**Table 2**  
Clusters showing significantly changed cortical thickness in the heroin-dependent individuals (HDIs) compared to the healthy controls (HCs). The symbol † (‡) indicates significantly increased (decreased) cortical thickness in the HDIs. CWP:  $p$ -value of the cluster (cluster-wise  $p$ -value). LH (RH), left (right) hemisphere.

Index	Cluster	Change in cortical thickness in HDIs	Cluster size (mm <sup>2</sup> )	STD of thickness in HDIs	Talairach coordinates			CWP	
					x	y	z		
LH	C1	Caudal middle frontal, precentral	↓	1859.1	0.288	−30.8	9.3	53.6	0.0001
	C2	Superior frontal	↓	1419.2	0.258	−11.2	10.6	61.7	0.0001
	C3	Superior parietal, precuneus	↓	2046.3	0.357	−16.2	−66.7	59.2	0.0001
	C4	Lingual, pericalcarine	↑	1769.5	0.136	−16.7	−45.4	−3.9	0.0001
	C5	Temporal pole, entorhinal	↑	1088.2	0.337	−38.1	4.9	−31.1	0.0007
RH	C6	Insula, post-/pre-central	↓	1733.6	0.316	37.1	−13.0	1.8	0.0001
	C7	Superior frontal, anterior/posterior cingulate	↓	1711.2	0.304	13.8	22.4	30.5	0.0001
	C8	Superior/middle temporal	↓	1323.3	0.161	62.5	−16.0	−0.1	0.0001
	C9	Lateral occipital	↑	1882.9	0.326	35.0	−84.6	−7.4	0.0001
	C10	Inferior parietal	↑	912.7	0.197	43.2	−53.6	42.5	0.0015
	C11	Cuneus, lateral occipital	↑	845.4	0.296	8.5	−84.1	19.4	0.0029
	C12	Lingual	↑	728.5	0.292	23.4	−54.1	−6.7	0.0087



**Fig. 1.** Vertex-wise analysis of cortical thickness in the heroin-dependent individuals (HDIs) compared to the healthy controls (HCs). (a) Clusters showing statistically significant between-group differences ( $p < 0.05$ ). Clusters color-coded in green (red) indicate significantly decreased (increased) cortical thickness in the HDIs. (b) Scatter plot of the mean cortical thickness values of the clusters in the right superior frontal (SFC.R) and the right insular (INS.R) regions changing with the duration of heroin use in the HDIs. The correlation analysis was only performed for the HDIs. For illustrative purposes, we also plotted the cortical thickness at the SFC.R and INS.R for the HCs. The symbol  $\circ$  in red (green) represents subjects in the HDIs (HCs). LH (RH), left (right) hemisphere.

users and a group of healthy controls. The vertex-wise SBM analysis indicated that compared to the HCs, the HDIs showed significantly decreased cortical thickness in clusters primarily located in the anterior portions of the brain, including several clusters in the frontal and temporal cortices as well as in the insula but significantly increased cortical thickness primarily in the posterior portions of the brain, in the parietal, lingual, cuneus and occipital cortices (Fig. 1). We also found that the cortical thickness in the right superior frontal and the right insular regions was negatively correlated with the duration of heroin use. Similarly, the ROI-wise SBM analysis, which was performed using the Destrieux cortical atlas, detected significantly reduced cortical thickness in the frontal, precuneus, calcarine, insular and occipital-temporal and lingual regions in the HDIs compared to the HCs.

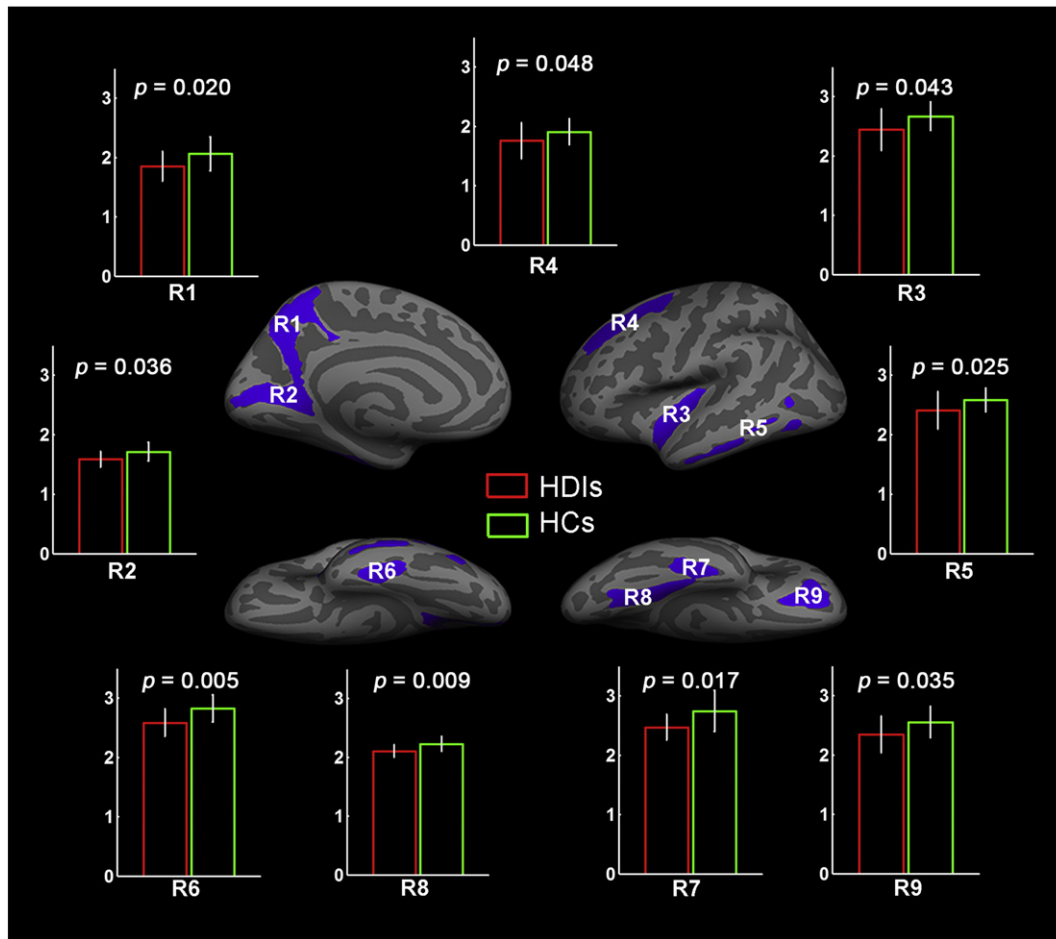
#### Alterations in brain morphometry

##### Vertex-wise analysis

We found significantly decreased cortical thickness in five clusters in the bilateral superior frontal (SFC), left caudal middle frontal (cmFC.L), right insular (INS.R), and right superior temporal (STC.R) regions in the HDIs compared to the HCs (Fig. 1a and Table 2). The SFC (extending to the ACC) and cmFC are located in the PFC. The PFC belongs to the cognitive control circuit which is one of four interdependent and overlapping circuits (a. reward: nucleus accumbens and ventral pallidum; b. memory and learning: AMYG and hippocampus; c. motivation: OFC; d. cognitive control: PFC and ACC) (Baler and Volkow, 2006). The findings of

abnormalities in the PFC could be helpful for understanding the neural mechanisms of addiction (Hyman et al., 2006; Kalivas and Volkow, 2005).

The PFC regulates the limbic reward circuit and is involved in higher-order cognitive function, including decision (Glascher et al., 2012; Walton et al., 2004), execution (McNamee et al., 2013), and attention (Asplund et al., 2010; Benoit et al., 2012; Squire et al., 2013). Previous neuroimaging and lesion studies in the human brain have revealed that disruption in the PFC can lead to either compulsive drug taking or disadvantageous behaviors associated with drug addiction (McGuire and Botvinick, 2010; Volkow and Li, 2004). What is more, because impairments in the PFC and ACC are associated with compulsive behaviors and impulsivity, dopamine's impaired modulation of these regions is likely to contribute to the compulsive and impulsive drug intake seen in addiction (Volkow and Fowler, 2000). Several fMRI studies indicated that the impairment in cognitive function and the degree of impairment in heroin addicts were related to changes in the activation of the prefrontal-cingulate network (Galynker et al., 2007; Lee et al., 2005; Xiao et al., 2006). Brain morphological studies also demonstrated structural abnormalities in the frontal cortex of drug users (Brody et al., 2004; Kim et al., 2006; Kuhn et al., 2010; Liu et al., 2009a; Lopez-Larson et al., 2011; Lyoo et al., 2006; Matochik et al., 2003). Using VBM, Lyoo et al. (2006) reported that the gray matter volume in the PFC of opiate-dependent subjects was significantly decreased compared to healthy controls and suggested that this may be associated with behavioral and neuropsychological dysfunction in drug users. Liu et al. (2009a) found significantly decreased gray matter



**Fig. 2.** ROI-wise analysis of cortical thickness in the heroin-dependent individuals (HDIs) compared to the healthy controls (HCs). Brain regions extracted from the Destrieux cortical atlas showing significant decreases in average thickness in the HDIs ( $p < 0.05$ ). The bar plot shows the between-group comparisons in cortical thickness in these nine regions. Bars and error bars color-coded in red (green) correspond to the averaged cortical thickness and the standard deviation of the HDIs (HCs). Labels R1–R9 correspond to the nine brain regions listed in Table 3.

volume in the PFC of heroin users compared to controls. Kuhn et al. (2010) and Lopez-Larson et al. (2011) detected significant decreases in cortical thickness in the PFC in smokers and marijuana users, respectively. Combined with these previous studies, our finding indicates that the frontal cortex is vulnerable to heroin addiction.

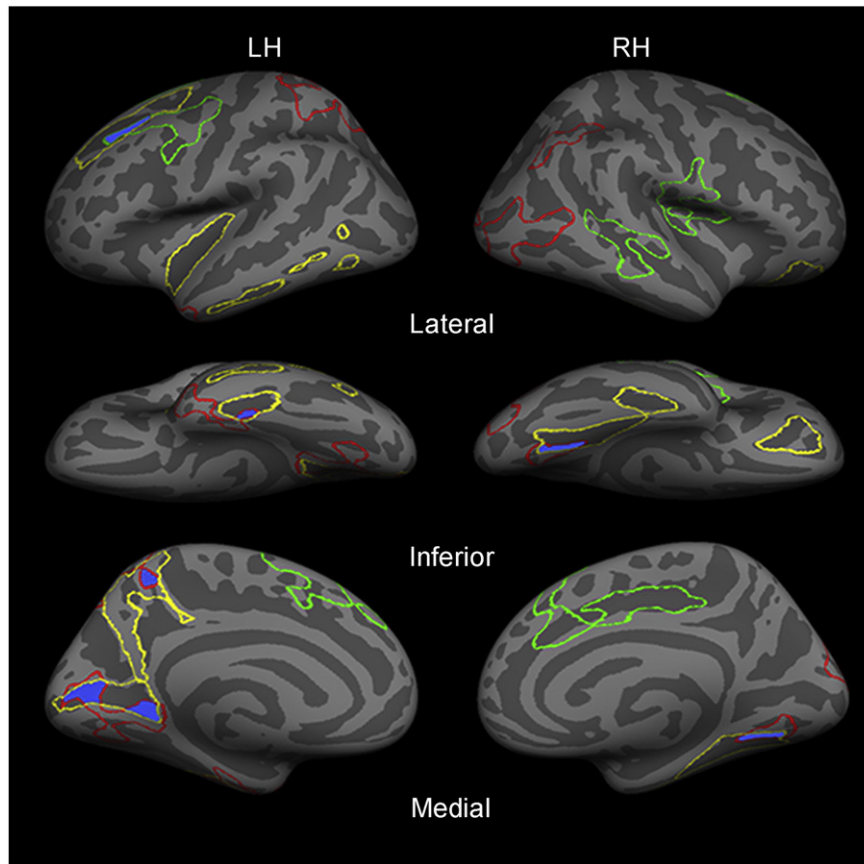
In this study, we also detected reductions in cortical thickness in the INS.R of the HDIs (Fig. 1a and Table 2), a finding which was in line with previous studies (Daglish et al., 2003; Hester et al., 2009; Mechtcheriakov et al., 2007; Weller et al., 2011). Daglish et al. (2003) studied opiate users while they were exposed to environmental cues and found abnormal brain activation in the INS. Hester et al. (2009) performed a Go/No-Go response inhibition task study in chronic cannabis users and found abnormal insular activity, suggesting that the INS is a key region related to the cognitive dysfunction and

behavioral deficits that maintain drug abuse. Lopez-Larson et al. (2011) found significantly decreased cortical thickness of the INS in adolescent marijuana users. Several studies (Contreras et al., 2007; Craig, 2009; Garavan, 2010; Menon and Uddin, 2010; Paulus et al., 2009) suggested that the INS plays a major role in the interoception and self-awareness that are usually related to emotion or the sensing and regulation of body states. A meta-analysis (Chang et al., 2013) also suggested that the INS can provide an interface between feelings, cognition, and action. Thus, the decreased cortical thickness in the INS may relate to a reduction in the subjects' ability to accurately perceive inner subjective feeling states, leading to increased impulsivity in drug use (Critchley et al., 2004).

Based on these descriptions of functional disruption in these two regions, inter-regional connections between the frontal cortex and the

**Table 3**  
Brain regions showing significant differences in cortical thickness between the heroin-dependent individuals (HDIs) and the healthy controls (HCs). The significant between-group differences in cortical thickness were determined at a significance level of  $p < 0.05$ . Labels R1–R9 indicate the locations of the nine regions listed in Fig. 2. LH (RH), left (right) hemisphere.

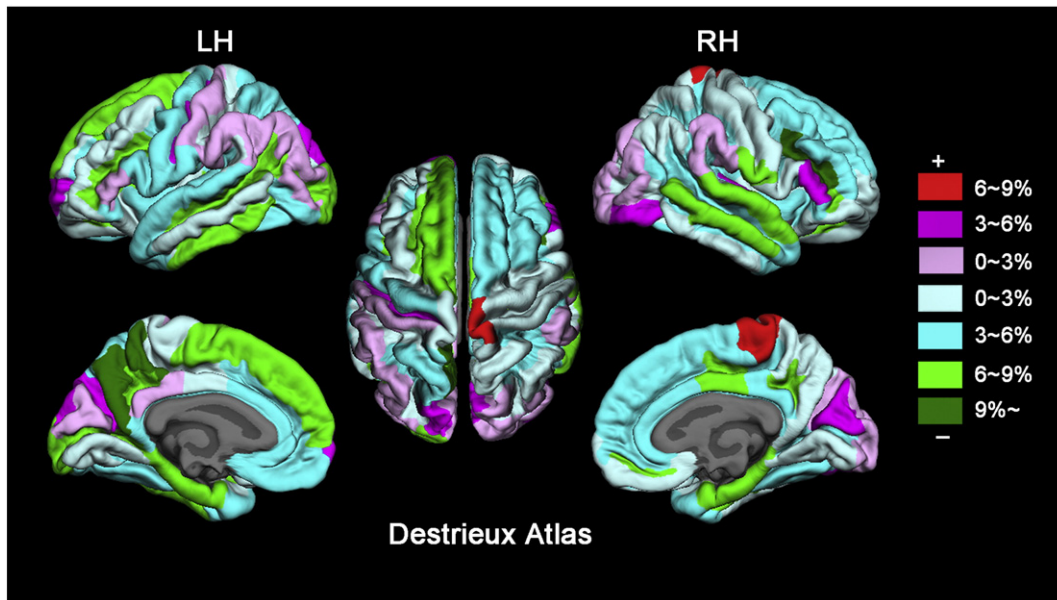
	Label	Brain regions	Absolute change in HDIs (mm)	Cluster size (mm <sup>2</sup> )	STD of thickness in HDIs	$p$ -value	
LH	R1	Precuneus gyrus	−0.214	2095.7	0.251	0.020	
	R2	Calcarine sulcus	−0.127	1309.8	0.131	0.036	
	R3	Inferior circular sulcus of insula	−0.226	1171.4	0.353	0.043	
	R4	Superior frontal sulcus	−0.148	2216.8	0.307	0.048	
	R5	Inferior temporal sulcus	−0.176	1461.2	0.317	0.025	
	R6	Anterior transverse collateral sulcus	−0.240	749.1	0.233	0.005	
	RH	R7	Anterior transverse collateral sulcus	−0.274	832.4	0.214	0.017
		R8	Medial occipitotemporal and lingual sulcus	−0.122	1485.3	0.111	0.009
		R9	Orbital sulci	−0.208	1274.9	0.311	0.035



**Fig. 3.** Areas of intersection (blue) representing abnormalities in the cortical thickness of the heroin-dependent individuals (HDIs) compared to the healthy controls (HCs) detected by using two different surface-wise morphometry (SBM) analyses: vertex-wise SBM and ROI-wise SBM analysis. The red (green) contour represents clusters with significantly increased (decreased) cortical thickness resulting from the vertex-wise SBM analysis (see Table 2). The yellow contour represents regions with significantly decreased cortical thickness resulting from the ROI-wise SBM analysis based on the Destrieux cortical atlas (see Table 3).

INS seem to constitute an important frontal–limbic network that is responsible for normal function of the control system, and plays a part in the conscious appreciation of pleasure (Clark et al., 2008; Mesulam, 2000).

In addition, drug use can trigger the release of dopamine, modulate the reward system, and reinforce the effects of drugs (Everitt and Robbins, 2005; Robbins and Everitt, 1999). The core clinical symptoms



**Fig. 4.** Relative changes in average cortical thickness in the heroin-dependent individuals (HDIs) compared to the healthy controls (HCs). The regions coded in warm (cold) colors indicate decreases (increases) in cortical thickness in the HDIs compared to the HCs. The analysis was based on every region of the Destrieux cortical atlas. LH (RH), left (right) hemisphere. The relative alteration of cortical thickness for a given ROI was estimated by  $RA = (HDIs - HCs) / HCs$ , in which the term HDIs (HCs) represents the group averaged cortical thickness in the HDIs (HCs) group for a given ROI.



**Table 4**  
Comparison of drug addiction-related alterations in brain structure obtained with voxel-based morphometry (VBM) and surface-based morphometry (SBM) analyses. The text highlighted (unhighlighted) in gray indicates significant increases (decreases) in gray matter volume or cortical thickness in the drug addicts compared to the controls.

Index	Subjects	Method	Regions significantly different from controls	Refs
1	Alcohol 22 users (56.3 years) 22 controls (53.7 years)	VBM	PreCG, MFG, INS, dHIP, THA, cerebellum	Mechtcheriakov et al. (2007)
2	Alcohol 9 users 21 controls	VBM	THA	Reid et al. (2008)
3	Alcohol 69 users (13.4 ± 1.9 years) 58 controls (13.0 ± 2.0 years)	SBM	IFC, STC, ITC, LOC, PCAL, PoCG, MTC.R, IPC.L, LING.R	Yang et al. (2012)
4	Cocaine 13 users (42 ± 6.3 years) 16 controls (32 ± 6.9 years)	VBM	AVI, vmOFC, ACC.R, STC	Franklin et al. (2002)
5	Cocaine 14 users (36.3 ± 4.7 years) 11 controls (33.8 ± 4.5 years)	VBM	ACC, mOFC.R, IOFC.R, PFC.R	Matochik et al. (2003)
6	Cocaine 19 users (39.5 ± 10.3 years) 17 controls (37.9 ± 12.9 years)	VBM	PFC, cerebellum.R	Brody et al. (2004)
7	Cocaine 22 users (30.8 ± 7.5 years) 23 controls (30.3 ± 7.9 years)	VBM	CC.R, THA.R, AG.R, MFC.L, CUN, IFC.L, FFG.L, PHG.L, STC.L, PoCG.L, LING, PCC.L	Gallinat et al. (2006)
8	Cocaine 40 users (41.4 ± 6.9 years) 41 controls (38.7 ± 8.8 years)	VBM	SFC, OFC.R, STC.R, ITG, THA.L, cerebellum	Sim et al. (2007)
9	Cocaine 20 users (33.4 ± 9.2 years) 16 controls (33.3 ± 6.9 years)	VBM	Striatum, SMG	Barros-Loscertales et al. (2011)
10	Cocaine 60 users (32.5 ± 8.5 years) 60 controls (32.3 ± 8.3 years)	VBM	OFC, INS, MFC, ACC, TPC, cerebellum Basal ganglia structures	Ersche et al. (2011)
11	Cocaine 38 users (29.6 ± 6.5 years) 38 controls (31.1 ± 5.1 years)	VBM	mFC.L, CC, IFG.R, CAU, MTC.L, ITC.L, INS.R, AMYG.L, HIP.L	Moreno-Lopez et al. (2012)
12	Cocaine 9 users (41.0 ± 5.7 years) 8 controls (39.5 ± 5.4 years)	VBM	DLPFC, ACC, INS, STC, cerebellum	Weller et al. (2011)
13	Cocaine 40 users (45 ± 6.3 years) 42 controls (39 ± 6.5 years)	VBM	OFC, DLPFC, HIP, temporal, PHG	Alia-Klein et al. (2011)
14	Cocaine 47 users (34.5 ± 7.4 years) 50 controls (32.8 ± 8.9 years)	VBM	STC, INS	Ersche et al. (2011)
15	Cocaine 20 users 20 controls	SBM	PFC.R, ACC.R, OFC.R, INS.R, PAC.R	Makris et al. (2008)
16	Cocaine 22 users (31.3 ± 7.8 years) 21 controls (30.9 ± 8.2 years)	SBM	mOFC.L	Kuhn et al. (2010)
17	Ketamine 41 users (26.9 ± 4.87 years) 44 controls (26.3 ± 5.84 years)	VBM	SFC.L, MFC.R	Liao et al. (2011)
18	Marijuana 11 users (25.4 ± 5.0 years) 8 controls (29.7 ± 4.7 years)	VBM	PHG.R PreCG, THA.R	Matochik et al. (2005)
19	Marijuana 18 users (17.8 ± 1.0 years) 18 controls (17.3 ± 0.8 years)	SBM	SFC, INS, cMFC.R PAC.L, LING, STC.R, SPC.R, IPC.R	Lopez-Larson et al. (2011)
20	Methamphetamine 29 users (36.5 ± 5.5 years) 20 controls (33.2 ± 6.5 years)	VBM	MFC.R	Kim et al. (2006)
21	Methamphetamine 17 users (35.1 ± 6.6 years) 20 controls (30.9 ± 8.2 years)	VBM	SFC.L, PreCG.L PUT, ISOC.R	Jan et al. (2012)
22	Methamphetamine 44 users (33.4 ± 8.4 years) 61 controls (34.1 ± 10.7 years)	VBM	INS, MFC.L ISLLL	Schwartz et al. (2010)
23	MDMA (Ecstasy) 31 users 29 controls	VBM	BA 18, BA 21.L, BA 45.L, cerebellum, midline brainstem	Cowan et al. (2003)
24	Amphetamine & Alcohol (40/40)	SBM	SFG.R, PreCG.L	Lawyer et al. (2010)



**Table 4** (continued)

Index	Subjects	Method	Regions significantly different from controls	Refs
25	Amphetamine-type stimulants 20 experienced users (EU) (26.6 ± 7.17 years) 42 low exposure users (LEU) (23.5 ± 5.27 years) 16 controls (26.3 ± 4.11 years)	VBM	EU vs LEU: BA11&BA8.L, BA11 & BA32/24.R EU vs. HC: BA11&BA8.L, BA11&BA32/24.R	Daumann et al. (2011)
26	Amphetamine-type stimulant 20 experienced users (EU) (26.6 ± 7.17 years) 42 low exposure users (LEU) (23.5 ± 5.27 years) 16 controls (26.3 ± 4.11 years)	SBM	EU vs LEU: SFC.L EU vs. HC: SFC.L, PoCG.R	Koester et al. (2012)
27	Abstinent substance dependent 19 users (age: 33 ± 11 years), 20 controls (age: 35 ± 7 years)	VBM	mOFC.R	Tanabe et al. (2009)
28	Opiate 63 users (38.4 ± 9.4 years) 46 controls (38.4 ± 8.6 years)	VBM	SFC, MFC, UNC.R, INS, IFC.R, FFG.L, STC	Lyyo et al. (2006)
29	Heroin 30 users (25.0 ± 2.4 years) 34 controls (23.97 ± 2.69 years)	VBM	MFC.L, IFC, INS, REC.R, FFG.R, ACCL, cerebellum.R	Yuan et al. (2009)
30	Heroin 15 users (30.47 ± 6.17 years) 15 controls (30.53 ± 6.70 years)	VBM	BA9.R, BA6.L, BA24.R, BA24.L	Liu et al. (2009)
31	Heroin 18 users (36.11 ± 5.72 years) 15 controls (36.80 ± 8.53 years)	SBM	SFC, cMFC.L, STC.R, INS.R SPC.L, LING, TP.L, IPC.R, LING.R, LOC.R, CUN.R	Current study

(Abbreviations: L (R)—the left (right) hemisphere; ACC—anterior cingulate cortex; AG—angular gyrus; AMYG—amygdala; AVI—anteroventral insular; BA—Brodmann's areas; CAU—caudate; CC—cingulate cortex; cMFC—caudal middle frontal cortex; CUN—cuneus; dHIP—dorsal hippocampus; FFG—fusiform; HIP—hippocampus; MTC—middle temporal cortex; INS—insula; IFC—inferior frontal cortex; ISLL—inferior semi lunar lobule; ITC—inferior temporal cortex; IPC—inferior parietal cortex; LING—lingual; LOC—lateral occipital cortex; MFC—middle frontal cortex; mFC—medial frontal cortex; OFC—orbitofrontal cortex; IOFC—lateral orbitofrontal cortex; ISOC—lateral superior occipital cortex; mOFC—medial orbitofrontal cortex; vmOFC—Ventromedial orbitofrontal cortex; PAC—paracingulate cortex; PreCG—precentral; PCAL—paracalcarine; PCC—posterior cingulate cortex; PFC—prefrontal cortex; PHG—parahippocampus; PoCG—postcentral; PUT—putamen; REC—rectus gyrus; SFC—superior frontal cortex; SPC—superior parietal cortex; STC—superior temporal cortex; SMG—supramarginal gyrus; THA—thalamus; TP—temporal pole; TPC—temporoparietal cortex; UNC—uncus).

of drug dependence include intoxication, bingeing, withdrawal, and craving (Goldstein and Volkow, 2011). As the brain adapts to the drugs, areas responsible for judgment, learning, emotion, and memory are affected. Moreover, drug seeking behavior indicates a change from voluntary drug use to more habitual and compulsive drug use (Naqvi and Bechara, 2009). Everitt and Robbins (2005) proposed that this change may represent a transition in the control over drug seeking and drug taking behavior at the neural level from the PFC to the striatum. Regions such as the vmPFC and AMYG have also been implicated in processing the reward value of various stimuli, including interoceptive stimuli (Naqvi and Bechara, 2009; Naqvi et al., 2007). Thus, our findings of abnormal cortical thickness in both the PFC and the INS may be responsible for the failure of self-control and the compulsiveness and habituation of drug-taking in HDIs.

We also observed significantly decreased cortical thickness in the STC.R in the HDIs (Fig. 1a and Table 2). Previous studies suggested that the STC has been involved in the perception of emotions and that abnormalities in the STC may associate with comorbid mood symptoms of drug users, such as anxiety and anger (Liotti et al., 2000). The STC has also been found to be an important structure in a pathway that primarily consists of the AMYG and PFC, both of which are involved in cognition (Adolphs, 2003; Bigler et al., 2007; Takahashi et al., 2004). Another study suggested that the STC may play an important role in integrating previous actions and successful outcomes into people's decision-making strategies (Paulus et al., 2005). Therefore, abnormal cortical thickness in the STC may cause heroin users to be unable to make appropriate decisions when exposed to drug cues. Similar findings were also reported in several previous studies of addiction (Lyyo et al., 2006; Sim et al., 2007; Yuan et al., 2009). Using the VBM method, Lyyo et al. (2006) and Yuan et al. (2009) found significantly decreased gray matter volume in the STC in HDIs and suggested that the STC may be associated with heroin dependence. In order to compare our findings with previous studies, we listed a number of brain structural abnormalities that have been detected

in studies of people who were dependent on other drugs in Table 4. We noticed that structural abnormalities were observed in the frontal, temporal, and insular regions in a number of drug dependencies, including alcohol (Yang et al., 2012), cocaine (Franklin et al., 2002), methylene dioxymeth-amphetamine (MDMA) (Cowan et al., 2003), and marijuana (Lopez-Larson et al., 2011). These consistent results suggest that different psychoactive drugs may be associated with abnormalities to the same brain regions, specifically, the SFC, cMFC, INS, and STC (see Table 4 for details).

In addition to this significantly decreased cortical thickness, we found significantly increased cortical thickness in seven clusters, three in the left hemisphere and four in the right hemisphere, in the HDIs compared to the HCs (Fig. 1a and Table 2). These regions included the bilateral lingual (LING), left superior parietal (SPC.L), left temporal pole (TP.L), right cuneus (CUN.R), right inferior parietal (IPC.R) and right lateral occipital (LOC.R) regions, which are primarily located in the posterior regions of the brain. These results were fairly consistent with previous studies. Lopez-Larson et al. (2011) investigated brain structural alterations in marijuana users and found significantly increased cortical thickness in the LING, STC, SPC, IPC, and paracentral regions. In an fMRI experimental study of active and abstinent marijuana users, Chang et al. (2006) detected greater activation in various frontal, parietal and occipital regions of both active and abstinent marijuana users compared to controls during visual-attention tasks and suggested that the drug-related greater activation may indicate the presence of neuroadaptive processes in the brains of drug users. Previous studies have also reported dysfunction of the parietal lobe in heroin users during the resting state. We noticed that the conclusions seem controversial (Danos et al., 1998; Pezawas et al., 2002). Pezawas et al. (2002) reported dysfunction of the parietal lobe with a significant increase in rCBF in heroin users during the resting state, while Danos et al. (1998) found that some of their patients showed hypoperfusion in the parietal lobe. As for the

CUN, a previous study suggested that it serves as visual processing and inhibitory control (Haldane et al., 2008) and its abnormality relates to neuroadaptation or possible compensatory changes. The finding of increased thickness in the CUN in this study may reflect that the cuneus compensates the damaged self-control to a certain extent.

From the information presented in Table 4, we also noticed that several clusters in the parietal, occipital, and lingual regions changed directions (Gallinat et al., 2006; Lopez-Larson et al., 2011; Matochik et al., 2005) in different studies. The reasons for these inconsistent results, in which different drug addiction groups either increased or decreased in their brain structural thickness, may be manifold and need to be further investigated.

#### ROI-wise analysis

Using an ROI-wise SBM analysis, we detected uniformly significantly decreased cortical thickness in nine regions in the HDIs compared to the HCs (Fig. 2 and Table 3). This analysis was based on the Destrieux cortical atlas which defines ROIs based on the gyri and sulci of the human brain. Both the ROI-wise and the vertex-wise SBM analyses revealed significant abnormalities in cortical thickness in the left superior frontal sulcus, left precuneus gyrus, left calcarine sulcus, left inferior circular insular sulcus, and the right medial occipital–temporal and lingual sulcus (Tables 2 and 3, Figs. 1 and 2). Our findings of decreased cortical thickness in the SFC and INS using either a vertex-wise analysis or an ROI-wise analysis may indicate that the SFC and INS are vulnerable to heroin dependence.

Unfortunately, we noticed two discrepancies in our findings (Tables 2 and 3, Figs. 1–3) when comparing the vertex-wise results with the ROI-wise results. One discrepancy is the location of areas of altered thickness. As shown in Fig. 3, we found that some clusters derived from the vertex-wise analysis did not correspond to the regions derived from the ROI-wise analysis, and the regions identified with the ROI-wise analysis, such as the left inferior temporal sulcus, right orbital sulci, and bilateral anterior transverse collateral sulcus, did not show up in the vertex-wise analysis (Fig. 3). This apparent inconsistency in the locations of altered thickness between the vertex- and the ROI-wise SBM analyses may have occurred because the clusters determined from the vertex-wise analysis did not overlap physically with the regions in the Destrieux atlas, which was used in the ROI-wise analysis. The other discrepancy is the direction of the alterations in cortical thickness in the HDIs compared to the HCs. As seen in Table 3, we found uniformly significantly reduced thickness in 9 ROIs in the HDIs compared with the controls when using the ROI-wise analysis. However, as shown in Table 2, five clusters decreased and seven clusters increased in thickness in the HDIs compared to the HCs according to the results from the vertex-wise analysis. This means that the direction of the thickness alteration detected in the HDIs was less variable using the ROI-wise analysis than using the vertex-wise analysis.

The discrepancy may be explained by checking the procedures of the two SBM analyses. Differences in the procedures used in the vertex-wise and ROI-wise analyses are likely to cause differences in the degree of variability in thickness estimates because of the influence of spatial averaging on thickness estimates (Eyler et al., 2012). For the vertex-wise estimates, the process of spatial averaging is equal to the spatial smoothing which was used in normalizing the cortical surface with a Gaussian kernel (FWHM = 10 mm in our study), and the amount of spatial averaging is fixed. On the other hand, in the ROI-wise analysis, we first averaged the cortical thickness across all the vertices within a region, as defined using a gyral-featured parcellation system, the Destrieux atlas, and then compared the cortical thickness between the two groups. For the ROI-wise estimates, the amount of spatial averaging varied between regions, the ROIs ranged in size from small (the left anterior transverse collateral sulcus, 749 mm<sup>2</sup>) to large (the left superior frontal sulcus, 2217 mm<sup>2</sup>) in Table 3. As a result, the variability or inhomogeneity differed as a result of varying region size (Table 3). The difference between the sensitivity of these two SBM analyses to variations in thickness may be important because the boundaries between regions have individual differences, which may have an impact

on the thickness measurement in the ROI-wise approach (see Inline Supplementary Tables S2 and S3 in the Supplementary material, comparing results derived from the Destrieux Atlas and the Desikan–Kiliany Atlas). Generally speaking, the ROI-wise SBM analysis provided a complementary perspective to the findings derived from the vertex-wise SBM analysis. In reality, no gold standard exists to evaluate which method is best, so we combined these two SBM analyses to explore the effects of heroin use on cortical changes in HDIs. Thus, interpretations about how thickness varies from region to region should be made cautiously, keeping in mind the possible effects of spatial averaging and boundary inaccuracy.

Inline Supplementary Tables S2 and S3 can be found online at <http://dx.doi.org/10.1016/j.neuroimage.2013.10.021>.

#### Correlation analysis

Correlations between cortical thickness and the duration of heroin use may indicate the influence of heroin use on brain structural alterations. We found that in the SFC.R the cortical thickness was significantly negatively correlated with the duration of heroin use and that in the INS.R it was marginally significantly negatively correlated with the duration of heroin use (Fig. 1b). That is, the longer the duration of heroin use, the thinner the cortical thickness in the SFC.R and INS.R. This result is consistent with previous studies (Ersche et al., 2011; Liao et al., 2011; Monterosso et al., 2005; Yuan et al., 2009). Monterosso et al. (2005) performed a stop-signal task study in chronic methamphetamine abuse subjects and found a negative correlation between years of methamphetamine use and performance in the task. Yuan et al. (2009) analyzed alterations in brain structure in HDIs by using an optimized VBM and partial correlation analysis and also found that the gray matter volume in the prefrontal and insular regions negatively correlated with the duration of heroin use. Therefore, the correlations between cortical thickness and duration in the SFC.R and INS.R may indicate that the duration of heroin use might be a critical factor associated with abnormalities in these two brain regions.

#### Limitations

This study has several limitations. First, because this was a cross-sectional study, we detected abnormal cortical thickness in the HDIs and inferred that the abnormalities might be due to heroin consumption. In reality, we cannot conclusively clarify the causal relationship; that is, we cannot be certain whether cortical thickness differences are a consequence of or a cause of heroin use (Ersche et al., 2012). Second, some of the HDIs in the present study also used nicotine (only four HDIs were non-smokers in this study), which may confound the results. Although we took nicotine as a covariate in our analysis, this process cannot remove the possibility that nicotine use had an independent effect on the alterations that we found in the HDIs brain structure. To address this issue, we may need to recruit non-nicotine users in future studies. Third, we cannot exclude the possible effect of methadone use on brain structure, although no significant correlation was found between the methadone dosage and the cortical thickness in this study. Also we could not assess the influence of withdrawal symptoms on the cortical thickness, because we did not quantitatively measure them with specific scales. No doubt, these issues should be considered in the future study. Last but not the least, the sample size in this study was small and the gender composition imbalanced. Although some studies have explored gender differences in the dysfunction of structure and function induced by drug use (McQueeney et al., 2011; Nelson-Zlupko et al., 1995; Thatcher et al., 2010), any gender effects on brain structural alterations in the HDIs remains an open question for further study.

## Conclusion

In summary, using a surface-based morphometric analysis, we detected alterations in the cortical thickness of the prefrontal cortex (SFC and cMFC) and insula as well as in some regions of the temporal, parietal and occipital cortices in heroin-dependent individuals. These findings were consistent with previous studies that have demonstrated abnormalities in these key brain regions in substance abuse. To the best of our knowledge, this is one of the first studies to evaluate cortical thickness in HDIs compared to non-users. Our findings suggest that abnormal cortical thickness in the prefrontal and insular regions may affect the capacity for self-control and contribute to conscious drug urges that occur in spite of the negative consequences. We also detected negative correlations between the duration of heroin use and the average thickness in the right superior frontal and insular regions. These results may add important information to the sparse literature on brain structural alterations in heroin users. Moreover, these findings may also provide implications for clinical treatment that could include finding intervention methods or medical treatments that restore the regions showing abnormal thickness to normal and, in this way, potentially reduce the symptoms of addiction or reduce the severity of addiction.

## Acknowledgments

This work was partly supported by the Guangdong No. 2 Provincial People's Hospital, funding from the National Natural Science Foundation of China (Grant numbers: 81071149, 81271548, and 81371535), the Science and Technology Planning Project of Guangdong Province, China (Grant numbers: 2011B031800044 and 2010B031600116), and Scientific Research Foundation for the Returned Overseas Chinese Scholars (RH), State Education Ministry. The authors appreciate the editing assistance of Drs. Rhoda E. and Edmund F. Peruzzi. The authors thank the two anonymous reviewers for their constructive comments and their suggestions.

## Competing interest's statement

The authors declare no competing financial interests.

## Appendix A. Supplementary data

Supplementary data to this article can be found online at <http://dx.doi.org/10.1016/j.neuroimage.2013.10.021>.

## References

- Adolphs, R., 2003. Cognitive neuroscience of human social behaviour. *Nat. Rev. Neurosci.* 4, 165–178.
- Almeida, L.G., Ricardo-Garcell, J., Prado, H., Barajas, L., Fernandez-Bouzas, A., Avila, D., Martinez, R.B., 2010. Reduced right frontal cortical thickness in children, adolescents and adults with ADHD and its correlation to clinical variables: a cross-sectional study. *J. Psychiatr. Res.* 44, 1214–1223.
- Asplund, C.L., Todd, J.J., Snyder, A.P., Marois, R., 2010. A central role for the lateral prefrontal cortex in goal-directed and stimulus-driven attention. *Nat. Neurosci.* 13, 507–512.
- Baler, R.D., Volkow, N.D., 2006. Drug addiction: the neurobiology of disrupted self-control. *Trends Mol. Med.* 12, 559–566.
- Barros-Loscertales, A., Garavan, H., Bustamante, J.C., Ventura-Campos, N., Llopi, J.J., Belloch, V., Parcet, M.A., Avila, C., 2011. Reduced striatal volume in cocaine-dependent patients. *Neuroimage* 56, 1021–1026.
- Benoit, R.G., Gilbert, S.J., Frith, C.D., Burgess, P.W., 2012. Rostral prefrontal cortex and the focus of attention in prospective memory. *Cereb. Cortex* 22, 1876–1886.
- Bigler, E.D., Mortensen, S., Neeley, E.S., Ozonoff, S., Krasny, L., Johnson, M., Lu, J., Provencal, S.L., McMahon, W., Lainhart, J.E., 2007. Superior temporal gyrus, language function, and autism. *Dev. Neuropsychol.* 31, 217–238.
- Bookstein, F.L., 2001. "Voxel-based morphometry" should not be used with imperfectly registered images. *Neuroimage* 14, 1454–1462.
- Brody, A.L., Mandelkern, M.A., London, E.D., Childress, A.R., Lee, G.S., Bota, R.G., Ho, M.L., Saxena, S., Baxter Jr., L.R., Madsen, D., Jarvik, M.E., 2002. Brain metabolic changes during cigarette craving. *Arch. Gen. Psychiatry* 59, 1162–1172.
- Brody, A.L., Mandelkern, M.A., Jarvik, M.E., Lee, G.S., Smith, E.C., Huang, J.C., Bota, R.G., Bartzokis, G., London, E.D., 2004. Differences between smokers and nonsmokers in regional gray matter volumes and densities. *Biol. Psychiatry* 55, 77–84.
- Chang, L., Yakupov, R., Cloak, C., Ernst, T., 2006. Marijuana use is associated with a reorganized visual-attention network and cerebellar hypoactivation. *Brain* 129, 1096–1112.
- Chang, L.J., Yarkoni, T., Khaw, M.W., Sanfey, A.G., 2013. Decoding the role of the insula in human cognition: functional parcellation and large-scale reverse inference. *Cereb. Cortex* 23, 739–749.
- Clark, L., Bechara, A., Damasio, H., Aitken, M.R., Sahakian, B.J., Robbins, T.W., 2008. Differential effects of insular and ventromedial prefrontal cortex lesions on risky decision-making. *Brain* 131, 1311–1322.
- Clarkson, M.J., Cardoso, M.J., Ridgway, G.R., Modat, M., Leung, K.K., Rohrer, J.D., Fox, N.C., Ourselin, S., 2011. A comparison of voxel and surface based cortical thickness estimation methods. *Neuroimage* 57, 856–865.
- Contreras, M., Ceric, F., Torrealba, F., 2007. Inactivation of the interoceptive insula disrupts drug craving and malaise induced by lithium. *Science* 318, 655–658.
- Cowan, R.L., Lyoo, I.K., Sung, S.M., Ahn, K.H., Kim, M.J., Hwang, J., Haga, E., Vimal, R.L., Lukas, S.E., Renshaw, P.F., 2003. Reduced cortical gray matter density in human MDMA (Ecstasy) users: a voxel-based morphometry study. *Drug Alcohol Depend.* 72, 225–235.
- Craig, A.D., 2009. How do you feel—now? The anterior insula and human awareness. *Nat. Rev. Neurosci.* 10, 59–70.
- Critchley, H.D., Wiens, S., Rotsstein, P., Ohman, A., Dolan, R.J., 2004. Neural systems supporting interoceptive awareness. *Nat. Neurosci.* 7, 189–195.
- Daglish, M.R., Weinstein, A., Malizia, A.L., Wilson, S., Melichar, J.K., Lingford-Hughes, A., Myles, J.S., Grasby, P., Nutt, D.J., 2003. Functional connectivity analysis of the neural circuits of opiate craving: "more" rather than "different"? *Neuroimage* 20, 1964–1970.
- Dale, A.M., Fischl, B., Sereno, M.I., 1999. Cortical surface-based analysis. I. Segmentation and surface reconstruction. *Neuroimage* 9, 179–194.
- Danos, P., Kasper, S., Grunwald, F., Klemm, E., Krappel, C., Broich, K., Hofflich, G., Overbeck, B., Biersack, H.J., Moller, H.J., 1998. Pathological regional cerebral blood flow in opiate-dependent patients during withdrawal: a HMPAO-SPECT study. *Neuropsychobiology* 37, 194–199.
- Daumann, J., Koester, P., Becker, B., Wagner, D., Imperati, D., Gouzoulis-Mayfrank, E., Tittgemeyer, M., 2011. Medial prefrontal gray matter volume reductions in users of amphetamine-type stimulants revealed by combined tract-based spatial statistics and voxel-based morphometry. *Neuroimage* 54, 794–801.
- Desikan, R.S., Segonne, F., Fischl, B., Quinn, B.T., Dickerson, B.C., Blacker, D., Buckner, R.L., Dale, A.M., Maguire, R.P., Hyman, B.T., Albert, M.S., Killiany, R.J., 2006. An automated labeling system for subdividing the human cerebral cortex on MRI scans into gyral based regions of interest. *Neuroimage* 31, 968–980.
- Destrieux, C., Fischl, B., Dale, A., Halgren, E., 2010. Automatic parcellation of human cortical gyri and sulci using standard anatomical nomenclature. *Neuroimage* 53, 1–15.
- Dickerson, B.C., Fenstermacher, E., Salat, D.H., Wolk, D.A., Maguire, R.P., Desikan, R., Pacheco, J., Quinn, B.T., Van der Kouwe, A., Greve, D.N., Blacker, D., Albert, M.S., Killiany, R.J., Fischl, B., 2008. Detection of cortical thickness correlates of cognitive performance: reliability across MRI scan sessions, scanners, and field strengths. *Neuroimage* 39, 10–18.
- Ersche, K.D., Fletcher, P.C., Roiser, J.P., Fryer, T.D., London, M., Robbins, T.W., Sahakian, B.J., 2006. Differences in orbitofrontal activation during decision-making between methadone-maintained opiate users, heroin users and healthy volunteers. *Psychopharmacology (Berl)* 188, 364–373.
- Ersche, K.D., Barnes, A., Jones, P.S., Morein-Zamir, S., Robbins, T.W., Bullmore, E.T., 2011. Abnormal structure of frontostriatal brain systems is associated with aspects of impulsivity and compulsivity in cocaine dependence. *Brain* 134, 2013–2024.
- Ersche, K.D., Jones, P.S., Williams, G.B., Turton, A.J., Robbins, T.W., Bullmore, E.T., 2012. Abnormal brain structure implicated in stimulant drug addiction. *Science* 335, 601–604.
- Everitt, B.J., Robbins, T.W., 2005. Neural systems of reinforcement for drug addiction: from actions to habits to compulsion. *Nat. Neurosci.* 8, 1481–1489.
- Eyler, L.T., Chen, C.H., Panizzon, M.S., Fennema-Notestine, C., Neale, M.C., Jak, A., Jernigan, T.L., Fischl, B., Franz, C.E., Lyons, M.J., Grant, M., Prom-Wormley, E., Seidman, L.J., Tsuang, M.T., Fiecas, M.J., Dale, A.M., Kremen, W.S., 2012. A comparison of heritability maps of cortical surface area and thickness and the influence of adjustment for whole brain measures: a magnetic resonance imaging twin study. *Twin Res. Hum. Genet.* 15, 304–314.
- Filbey, F.M., Schacht, J.P., Myers, U.S., Chavez, R.S., Hutchison, K.E., 2009. Marijuana craving in the brain. *Proc. Natl. Acad. Sci. U. S. A.* 106, 13016–13021.
- Fischl, B., Sereno, M.I., Dale, A.M., 1999a. Cortical surface-based analysis. II: Inflation, flattening, and a surface-based coordinate system. *Neuroimage* 9, 195–207.
- Fischl, B., Sereno, M.I., Tootell, R.B., Dale, A.M., 1999b. High-resolution intersubject averaging and a coordinate system for the cortical surface. *Hum. Brain Mapp.* 8, 272–284.
- Fischl, B., van der Kouwe, A., Destrieux, C., Halgren, E., Segonne, F., Salat, D.H., Busa, E., Seidman, L.J., Goldstein, J., Kennedy, D., Caviness, V., Makris, N., Rosen, B., Dale, A.M., 2004. Automatically parcellating the human cerebral cortex. *Cereb. Cortex* 14, 11–22.
- Franklin, T.R., Acton, P.D., Maldjian, J.A., Gray, J.D., Croft, J.R., Dackis, C.A., O'Brien, C.P., Childress, A.R., 2002. Decreased gray matter concentration in the insular, orbitofrontal, cingulate, and temporal cortices of cocaine patients. *Biol. Psychiatry* 51, 134–142.
- Fu, L.P., Bi, G.H., Zou, Z.T., Wang, Y., Ye, E.M., Ma, L., Ming, F., Yang, Z., 2008. Impaired response inhibition function in abstinent heroin dependents: an fMRI study. *Neurosci. Lett.* 438, 322–326.
- Gallinat, J., Meisenzahl, E., Jacobsen, L.K., Kalus, P., Bierbrauer, J., Kienast, T., Witthaus, H., Leopold, K., Seifert, F., Schubert, F., Staedtgen, M., 2006. Smoking and structural brain deficits: a volumetric MR investigation. *Eur. J. Neurosci.* 24, 1744–1750.



- Galynker, I.I., Eisenberg, D., Matochik, J.A., Gertmenian-King, E., Cohen, L., Kimes, A.S., Contoreggi, C., Kurian, V., Ernst, M., Rosenthal, R.N., Prosser, J., London, E.D., 2007. Cerebral metabolism and mood in remitted opiate dependence. *Drug Alcohol Depend.* 90, 166–174.
- Garavan, H., 2010. Insula and drug cravings. *Brain Struct. Funct.* 214, 593–601.
- Glaser, J., Adolphs, R., Damasio, H., Bechara, A., Rudrauf, D., Calamia, M., Paul, L.K., Tranel, D., 2012. Lesion mapping of cognitive control and value-based decision making in the prefrontal cortex. *Proc. Natl. Acad. Sci. U. S. A.* 109, 14681–14686.
- Glasser, M.F., Sotiropoulos, S.N., Wilson, J.A., Coalson, T.S., Fischl, B., Andersson, J.L., Xu, J., Jbabdi, S., Webster, M., Polimeni, J.R., Van Essen, D.C., Jenkinson, M., 2013. The minimal preprocessing pipelines for the Human Connectome Project. *Neuroimage* 80, 105–124.
- Goldstein, R.Z., Volkow, N.D., 2002. Drug addiction and its underlying neurobiological basis: neuroimaging evidence for the involvement of the frontal cortex. *Am. J. Psychiatry* 159, 1642–1652.
- Goldstein, R.Z., Volkow, N.D., 2011. Dysfunction of the prefrontal cortex in addiction: neuroimaging findings and clinical implications. *Nat. Rev. Neurosci.* 12, 652–669.
- Goldstein, R.Z., Craig, A.D., Bechara, A., Garavan, H., Childress, A.R., Paulus, M.P., Volkow, N.D., 2009. The neurocircuitry of impaired insight in drug addiction. *Trends Cogn. Sci.* 13, 372–380.
- Habets, P., Marcelis, M., Gronenschild, E., Drukker, M., van Os, J., 2011. Reduced cortical thickness as an outcome of differential sensitivity to environmental risks in schizophrenia. *Biol. Psychiatry* 69, 487–494.
- Haldane, M., Cunningham, G., Androutsos, C., Frangou, S., 2008. Structural brain correlates of response inhibition in Bipolar Disorder I. *J. Psychopharmacol.* 22, 138–143.
- Hester, R., Nestor, L., Garavan, H., 2009. Impaired error awareness and anterior cingulate cortex hypoactivity in chronic cannabis users. *Neuropsychopharmacology* 34, 2450–2458.
- Hutton, C., Draganski, B., Ashburner, J., Weiskopf, N., 2009. A comparison between voxel-based cortical thickness and voxel-based morphometry in normal aging. *Neuroimage* 48, 371–380.
- Hyman, S.E., Malenka, R.C., Nestler, E.J., 2006. Neural mechanisms of addiction: the role of reward-related learning and memory. *Annu. Rev. Neurosci.* 29, 565–598.
- Jan, R., Lin, J., Miles, S., Kydd, R., Russell, B., 2012. Striatal volume increases in active methamphetamine-dependent individuals and correlation with cognitive performance. *Brain Sci.* 2, 553–572.
- Jednorog, K., Altarelli, I., Monzalvo, K., Fluss, J., Dubois, J., Billard, C., Dehaene-Lambertz, G., Ramus, F., 2012. The influence of socioeconomic status on children's brain structure. *PLoS One* 7, e42486.
- Jones, D.K., Symms, M.R., Cercignani, M., Howard, R.J., 2005. The effect of filter size on VBM analyses of DT-MRI data. *Neuroimage* 26, 546–554.
- Kalivas, P.W., Volkow, N.D., 2005. The neural basis of addiction: a pathology of motivation and choice. *Am. J. Psychiatry* 162, 1403–1413.
- Kallianpur, K.J., Kirk, G.R., Sailasuta, N., Valcour, V., Shiramizu, B., Nakamoto, B.K., Shikuma, C., 2012. Regional cortical thinning associated with detectable levels of HIV DNA. *Cereb. Cortex* 22, 2065–2075.
- Kilts, C.D., Schweitzer, J.B., Quinn, C.K., Gross, R.E., Faber, T.L., Muhammad, F., Ely, T.D., Hoffman, J.M., Drexler, K.P., 2001. Neural activity related to drug craving in cocaine addiction. *Arch. Gen. Psychiatry* 58, 334–341.
- Kim, S.J., Lyoo, I.K., Hwang, J., Chung, A., Hoon Sung, Y., Kim, J., Kwon, D.H., Chang, K.H., Renshaw, P.F., 2006. Prefrontal grey-matter changes in short-term and long-term abstinent methamphetamine abusers. *Int. J. Neuropsychopharmacol.* 9, 221–228.
- Klein, A., Ghosh, S.S., Avants, B., Yeo, B.T., Fischl, B., Ardekani, B., Gee, J.C., Mann, J.J., Parsey, R.V., 2010. Evaluation of volume-based and surface-based brain image registration methods. *Neuroimage* 51, 214–220.
- Koester, P., Tittgemeyer, M., Wagner, D., Becker, B., Gouzoulis-Mayfrank, E., Daumann, J., 2012. Cortical thinning in amphetamine-type stimulant users. *Neuroscience* 221, 182–192.
- Kuhn, S., Schubert, F., Gallinat, J., 2010. Reduced thickness of medial orbitofrontal cortex in smokers. *Biol. Psychiatry* 68, 1061–1065.
- Lawyer, G., Bjerkan, P.S., Hammarberg, A., Jayaram-Lindstrom, N., Franck, J., Agartz, I., 2010. Amphetamine dependence and co-morbid alcohol abuse: associations to brain cortical thickness. *BMC Pharmacol.* 10, 5.
- Lee, T.M., Pau, C.W., 2002. Impulse control differences between abstinent heroin users and matched controls. *Brain Inj.* 16, 885–889.
- Lee, T.M., Liu, H.L., Feng, C.M., Hou, J., Mahankali, S., Fox, P.T., Gao, J.H., 2001. Neural correlates of response inhibition for behavioral regulation in humans assessed by functional magnetic resonance imaging. *Neurosci. Lett.* 309, 109–112.
- Lee, T.M., Zhou, W.H., Luo, X.J., Yuen, K.S., Ruan, X.Z., Weng, X.C., 2005. Neural activity associated with cognitive regulation in heroin users: a fMRI study. *Neurosci. Lett.* 382, 211–216.
- Liao, Y., Tang, J., Corlett, P.R., Wang, X., Yang, M., Chen, H., Liu, T., Chen, X., Hao, W., Fletcher, P.C., 2011. Reduced dorsal prefrontal gray matter after chronic ketamine use. *Biol. Psychiatry* 69, 42–48.
- Liotti, M., Mayberg, H.S., Brannan, S.K., McGinnis, S., Jerabek, P., Fox, P.T., 2000. Differential limbic-cortical correlates of sadness and anxiety in healthy subjects: implications for affective disorders. *Biol. Psychiatry* 48, 30–42.
- Liu, H., Hao, Y., Kaneko, Y., Ouyang, X., Zhang, Y., Xu, L., Xue, Z., Liu, Z., 2009a. Frontal and cingulate gray matter volume reduction in heroin dependence: optimized voxel-based morphometry. *Psychiatry Clin. Neurosci.* 63, 563–568.
- Liu, J., Liang, J., Qin, W., Tian, J., Yuan, K., Bai, L., Zhang, Y., Wang, W., Wang, Y., Li, Q., Zhao, L., Lu, L., von Deneen, K.M., Liu, Y., Gold, M.S., 2009b. Dysfunctional connectivity patterns in chronic heroin users: an fMRI study. *Neurosci. Lett.* 460, 72–77.
- Lopez-Larson, M.P., Bogorodzki, P., Rogowska, J., McGlade, E., King, J.B., Terry, J., Yurgelun-Todd, D., 2011. Altered prefrontal and insular cortical thickness in adolescent marijuana users. *Behav. Brain Res.* 220, 164–172.
- Lusebrink, F., Wollrab, A., Speck, O., 2013. Cortical thickness determination of the human brain using high resolution 3T and 7T MRI data. *Neuroimage* 70, 122–131.
- Lyoo, I.K., Pollack, M.H., Silveri, M.M., Ahn, K.H., Diaz, C.I., Hwang, J., Kim, S.J., Yurgelun-Todd, D.A., Kaufman, M.J., Renshaw, P.F., 2006. Prefrontal and temporal gray matter density decreases in opiate dependence. *Psychopharmacology (Berl)* 184, 139–144.
- Ma, N., Liu, Y., Li, N., Wang, C.X., Zhang, H., Jiang, X.F., Xu, H.S., Fu, X.M., Hu, X., Zhang, D.R., 2010. Addiction related alteration in resting-state brain connectivity. *Neuroimage* 49, 738–744.
- Makris, N., Gasic, G.P., Kennedy, D.N., Hodge, S.M., Kaiser, J.R., Lee, M.J., Kim, B.W., Blood, A.J., Evins, A.E., Seidman, L.J., Iosifescu, D.V., Lee, S., Baxter, C., Perlis, R.H., Smoller, J.W., Fava, M., Breiter, H.C., 2008. Cortical thickness abnormalities in cocaine addiction—a reflection of both drug use and a pre-existing disposition to drug abuse? *Neuron* 60, 174–188.
- Matochik, J.A., London, E.D., Eldreth, D.A., Cadet, J.L., Bolla, K.I., 2003. Frontal cortical tissue composition in abstinent cocaine abusers: a magnetic resonance imaging study. *Neuroimage* 19, 1095–1102.
- Matochik, J.A., Eldreth, D.A., Cadet, J.L., Bolla, K.I., 2005. Altered brain tissue composition in heavy marijuana users. *Drug Alcohol Depend.* 77, 23–30.
- McGuire, J.T., Botvinick, M.M., 2010. Prefrontal cortex, cognitive control, and the registration of decision costs. *PNAS* 107, 7922–7926.
- McNamee, D., Rangel, A., O'Doherty, J.P., 2013. Category-dependent and category-independent goal-value codes in human ventromedial prefrontal cortex. *Nat. Neurosci.* 16, 479–485.
- McQueeny, T., Padula, C.B., Price, J., Medina, K.L., Logan, P., Tapert, S.F., 2011. Gender effects on amygdala morphometry in adolescent marijuana users. *Behav. Brain Res.* 224, 128–134.
- Mechtcheriakov, S., Brenneis, C., Egger, K., Koppelstaetter, F., Schocke, M., Marksteiner, J., 2007. A widespread distinct pattern of cerebral atrophy in patients with alcohol addiction revealed by voxel-based morphometry. *J. Neurol. Neurosurg. Psychiatry* 78, 610–614.
- Menon, V., Uddin, L.Q., 2010. Saliency, switching, attention and control: a network model of insula function. *Brain Struct. Funct.* 214, 655–667.
- Messina, R., Rocca, M.A., Colombo, B., Valsasina, P., Horsfield, M.A., Copetti, M., Falini, A., Comi, G., Filippi, M., 2013. Cortical abnormalities in patients with migraine: a surface-based analysis. *Radiology* 268, 170–180.
- Mesulam, M., 2000. Brain, mind, and the evolution of connectivity. *Brain Cogn.* 42, 4–6.
- Monterosso, J.R., Aron, A.R., Cordova, X., Xu, J., London, E.D., 2005. Deficits in response inhibition associated with chronic methamphetamine abuse. *Drug Alcohol Depend.* 79, 273–277.
- Moreno-Lopez, L., Catena, A., Fernandez-Serrano, M.J., Delgado-Rico, E., Stamatakis, E.A., Perez-Garcia, M., Verdejo-Garcia, A., 2012. Trait impulsivity and prefrontal gray matter reductions in cocaine dependent individuals. *Drug Alcohol Depend.* 125, 208–214.
- Naqvi, N.H., Bechara, A., 2009. The hidden island of addiction: the insula. *Trends Neurosci.* 32, 56–67.
- Naqvi, N.H., Bechara, A., 2010. The insula and drug addiction: an interoceptive view of pleasure, urges, and decision-making. *Brain Struct. Funct.* 214, 435–450.
- Naqvi, N.H., Rudrauf, D., Damasio, H., Bechara, A., 2007. Damage to the insula disrupts addiction to cigarette smoking. *Science* 315, 531–534.
- Nelson-Zupko, L., Kauffman, E., Dore, M.M., 1995. Gender differences in drug addiction and treatment: implications for social work intervention with substance-abusing women. *Soc. Work* 40, 45–54.
- Palaniyappan, L., Liddle, P.F., 2012. Aberrant cortical gyrification in schizophrenia: a surface-based morphometry study. *J. Psychiatry Neurosci.* 37, 399–406.
- Paulus, M.P., Feinstein, J.S., Leland, D., Simmons, A.N., 2005. Superior temporal gyrus and insula provide response and outcome-dependent information during assessment and action selection in a decision-making situation. *Neuroimage* 25, 607–615.
- Paulus, M.P., Tapert, S.F., Schulteis, G., 2009. The role of interoception and alliesthesia in addiction. *Pharmacol. Biochem. Behav.* 94, 1–7.
- Pezawas, L., Fischer, G., Podreka, I., Schindler, S., Brucke, T., Jagsch, R., Thurnher, M., Kasper, S., 2002. Opioid addiction changes cerebral blood flow symmetry. *Neuropsychobiology* 45, 67–73.
- Pontious, A., Kowalczyk, T., Englund, C., Hevner, R.F., 2008. Role of intermediate progenitor cells in cerebral cortex development. *Dev. Neurosci.* 30, 24–32.
- Qiu, Y.W., Jiang, G.H., Su, H.H., Lv, X.F., Tian, J.Z., Li, L.M., Zhuo, F.Z., 2013. The impulsivity behavior is correlated with prefrontal cortex gray matter volume reduction in heroin-dependent individuals. *Neurosci. Lett.* 538, 43–48.
- Reid, A.G., Dalgligh, M.R., Kempton, M.J., Williams, T.M., Watson, B., Nutt, D.J., Lingford-Hughes, A.R., 2008. Reduced thalamic gray matter volume in opioid dependence is influenced by degree of alcohol use: a voxel-based morphometry study. *J. Psychopharmacol.* 22, 7–10.
- Robbins, T.W., Everitt, B.J., 1999. Drug addiction: bad habits add up. *Nature* 398, 567–570.
- Schwartz, D.L., Mitchell, A.D., Lahna, D.L., Luber, H.S., Huckans, M.S., Mitchell, S.H., Hoffman, W.F., 2010. Global and local morphometric differences in recently abstinent methamphetamine-dependent individuals. *Neuroimage* 50, 1392–1401.
- Shaw, P., Greenstein, D., Lerch, J., Clasen, L., Lenroot, R., Gogtay, N., Evans, A., Rapoport, J., Giedd, J., 2006. Intellectual ability and cortical development in children and adolescents. *Nature* 440, 676–679.
- Sim, M.E., Lyoo, I.K., Streeter, C.C., Covell, J., Sarid-Segal, O., Ciraulo, D.A., Kim, M.J., Kaufman, M.J., Yurgelun-Todd, D.A., Renshaw, P.F., 2007. Cerebellar gray matter volume correlates with duration of cocaine use in cocaine-dependent subjects. *Neuropsychopharmacol.* 32, 2229–2237.



- Sowell, E.R., Thompson, P.M., Leonard, C.M., Welcome, S.E., Kan, E., Toga, A.W., 2004. Longitudinal mapping of cortical thickness and brain growth in normal children. *J. Neurosci.* 24, 8223–8231.
- Spitzer, R.L., Williams, J.B., Gibbon, M., First, M.B., 1992. The Structured Clinical Interview for DSM-III-R (SCID). I: History, rationale, and description. *Arch. Gen. Psychiatry* 49, 624–629.
- Squire, R.F., Noudoost, B., Schafer, R.J., Moore, T., 2013. Prefrontal contributions to visual selective attention. *Annu. Rev. Neurosci.* 36, 451–466.
- Strangman, G.E., O'Neil-Pirozzi, T.M., Supelana, C., Goldstein, R., Katz, D.J., Glenn, M.B., 2010. Regional brain morphometry predicts memory rehabilitation outcome after traumatic brain injury. *Front. Hum. Neurosci.* 4, 182.
- Swann, A.C., Bjork, J.M., Moeller, F.G., Dougherty, D.M., 2002. Two models of impulsivity: relationship to personality traits and psychopathology. *Biol. Psychiatry* 51, 988–994.
- Takahashi, H., Yahata, N., Koeda, M., Matsuda, T., Asai, K., Okubo, Y., 2004. Brain activation associated with evaluative processes of guilt and embarrassment: an fMRI study. *Neuroimage* 23, 967–974.
- Tamnes, C.K., Ostby, Y., Fjell, A.M., Westlye, L.T., Due-Tønnessen, P., Walhovd, K.B., 2010. Brain maturation in adolescence and young adulthood: regional age-related changes in cortical thickness and white matter volume and microstructure. *Cereb. Cortex* 20, 534–548.
- Tanabe, J., Tregellas, J.R., Dalwani, M., Thompson, L., Owens, E., Crowley, T., Banich, M., 2009. Medial orbitofrontal cortex gray matter is reduced in abstinent substance-dependent individuals. *Biol. Psychiatry* 65, 160–164.
- Tang, Y.L., Zhao, D., Zhao, C., Cubells, J.F., 2006. Opiate addiction in China: current situation and treatments. *Addiction* 101, 657–665.
- Thatcher, D.L., Pajtek, S., Chung, T., Terwilliger, R.A., Clark, D.B., 2010. Gender differences in the relationship between white matter organization and adolescent substance use disorders. *Drug Alcohol Depend.* 110, 55–61.
- Van Essen, D.C., Smith, S.M., Barch, D.M., Behrens, T.E., Yacoub, E., Ugurbil, K., 2013. The WU-Minn Human Connectome Project: an overview. *Neuroimage* 80, 62–79.
- Voets, N.L., Hough, M.G., Douaud, G., Matthews, P.M., James, A., Winmill, L., Webster, P., Smith, S., 2008. Evidence for abnormalities of cortical development in adolescent-onset schizophrenia. *Neuroimage* 43, 665–675.
- Volkow, N.D., Fowler, J.S., 2000. Addiction, a disease of compulsion and drive: involvement of the orbitofrontal cortex. *Cereb. Cortex* 10, 318–325.
- Volkow, N.D., Li, T.K., 2004. Drug addiction: the neurobiology of behaviour gone awry. *Nat. Rev. Neurosci.* 5, 963–970.
- Volkow, N.D., Wang, G.J., Tomasi, D., Baler, R.D., 2013. Unbalanced neuronal circuits in addiction. *Curr. Opin. Neurobiol.* 23, 639–648.
- Walhovd, K.B., Moe, V., Slinning, K., Due-Tønnessen, P., Bjørnerud, A., Dale, A.M., van der Kouwe, A., Quinn, B.T., Kosofsky, B., Greve, D., Fischl, B., 2007. Volumetric cerebral characteristics of children exposed to opiates and other substances in utero. *Neuroimage* 36, 1331–1344.
- Walton, M.E., Devlin, J.T., Rushworth, M.F., 2004. Interactions between decision making and performance monitoring within prefrontal cortex. *Nat. Neurosci.* 7, 1259–1265.
- Wang, X., Li, B., Zhou, X., Liao, Y., Tang, J., Liu, T., Hu, D., Hao, W., 2012. Changes in brain gray matter in abstinent heroin addicts. *Drug Alcohol Depend.* 126, 304–308.
- Weller, R.E., Stoerckel, L.E., Milby, J.B., Bolding, M., Twieg, D.B., Knowlton, R.C., Avison, M.J., Ding, Z., 2011. Smaller regional gray matter volume in homeless African American cocaine-dependent men: a preliminary report. *Open Neuroimaging J.* 5, 57–64.
- Xiao, Z., Lee, T., Zhang, J.X., Wu, Q., Wu, R., Weng, X., Hu, X., 2006. Thirsty heroin addicts show different fMRI activations when exposed to water-related and drug-related cues. *Drug Alcohol Depend.* 83, 157–162.
- Yang, Z., Xie, J., Shao, Y.C., Xie, C.M., Fu, L.P., Li, D.J., Fan, M., Ma, L., Li, S.J., 2009. Dynamic neural responses to cue-reactivity paradigms in heroin-dependent users: an fMRI study. *Hum. Brain Mapp.* 30, 766–775.
- Yang, Y., Roussotte, F., Kan, E., Sulik, K.K., Mattson, S.N., Riley, E.P., Jones, K.L., Adnams, C.M., May, P.A., O'Connor, M.J., Narr, K.L., Sowell, E.R., 2012. Abnormal cortical thickness alterations in fetal alcohol spectrum disorders and their relationships with facial dysmorphism. *Cereb. Cortex* 22, 1170–1179.
- Yuan, Y., Zhu, Z., Shi, J., Zou, Z., Yuan, F., Liu, Y., Lee, T.M., Weng, X., 2009. Gray matter density negatively correlates with duration of heroin use in young lifetime heroin-dependent individuals. *Brain Cogn.* 71, 223–228.
- Yuan, K., Qin, W., Dong, M., Liu, J., Liu, P., Zhang, Y., Sun, J., Wang, W., Wang, Y., Li, Q., Yang, W., Tian, J., 2010a. Combining spatial and temporal information to explore resting-state networks changes in abstinent heroin-dependent individuals. *Neurosci. Lett.* 475, 20–24.
- Yuan, K., Qin, W., Dong, M., Liu, J., Sun, J., Liu, P., Zhang, Y., Wang, W., Wang, Y., Li, Q., Zhao, L., von Deneen, K.M., Liu, Y., Gold, M.S., Tian, J., 2010b. Gray matter deficits and resting-state abnormalities in abstinent heroin-dependent individuals. *Neurosci. Lett.* 482, 101–105.